

Molecular Analysis of Patients with Synostotic Frontal Plagiocephaly (Unilateral Coronal Synostosis)

John B. Mulliken, M.D., Karen W. Gripp, M.D., Catherine A. Stolle, Ph.D., Daniela Steinberger, M.D., and Ulrich Müller, M.D., Ph.D.

Boston, Mass.; Philadelphia, Pa.; and Giessen, Germany

Mutations in genes known to be responsible for most of the recognizable syndromes associated with bilateral coronal synostosis can be detected by molecular testing. The genetic alterations that could cause unilateral coronal synostosis are more elusive. It is recognized that *FGFR* and *TWIST* mutations can give rise to either bilateral or unilateral coronal synostosis, even in the same family. The authors undertook a prospective study of patients presenting with synostotic frontal plagiocephaly (unilateral coronal synostosis) to Children's Hospital Boston during the period from 1997 to 2000. Mutational analysis was performed on all patients and on selected parents whenever familial transmission was suspected. Intraoperative anthropometry was used in an effort to differentiate those patients in whom a mutation was detected from those in whom it was not. The anthropometric measures included bilateral sagittal orbital-globe distance, inter medial canthal distance, and nasal angulation. Macrocephaly and palpebral angulation were also considered possible determinants. There was a 2:1 female preponderance in 47 patients with synostotic frontal plagiocephaly. Mutations were found in eight of 47 patients: two patients with different single-amino-acid changes in *FGFR2*, three patients with *FGFR3* Pro250Arg, and three patients with *TWIST* mutations. Another patient had craniofrontonasal syndrome for which a causative locus has been mapped to chromosome X, although molecular testing is not yet available. Two features were strongly associated with a detectable mutation in patients with synostotic frontal plagiocephaly: asymmetrical brachycephaly (retrusion of both supraorbital rims) and orbital hypertelorism. Other abnormalities in the craniofacial region and extremities were clues to a particular mutation in *FGFR2*, *FGFR3*, *TWIST*, or the X-linked mutation. Neither macrocephaly nor degree of nasal angulation nor relative vertical position of the lateral canthi correlated with mutational detection. An additional four patients in this study had either unilateral or bilateral coronal synostosis in an immediate relative and had anthropometric findings that predicted a mutation, and yet no genetic alteration was found. This suggests either that the authors' screening methods

were not sufficiently sensitive or that perhaps there are other unknown pathogenic loci. Nevertheless, molecular testing is recommended for infants who have unilateral coronal synostosis, particularly if there are the anthropometric findings highlighted in this study or an otherwise suspicious feature in the child or a parent. Infants with either an identified or a suspected mutation usually need bilateral asymmetric advancement of the bandeau and may be more likely to require frontal revision in childhood. (*Plast. Reconstr. Surg.* 113: 1899, 2004.)

Synostotic frontal plagiocephaly is the phenotypic designation for premature closure of the frontoparietal and frontosphenoidal sutures on one side of the coronal ring. Unilateral coronal synostosis is the more commonly used clinicopathologic term.¹ This disorder is characterized by elevation and posterolateral displacement of the affected orbit, ipsilateral deviation of the nasal root, and contralateral compensatory frontal bossing. There is also a contralateral rotation of the middle face and mandible, as evidenced by anteriorly positioned auricle, malar eminence, and temporomandibular joint.² There are also rare instances of synostotic frontal plagiocephaly in which the frontoparietal suture is open and only the frontosphenoidal suture is fused. This localized synostosis in the basal coronal ring results in a flat forehead with minimal orbital displacement, straight nasal dorsum (or slight contralateral deviation), and minor midfacial rotation.³

From the Craniofacial Center, Division of Plastic Surgery, Children's Hospital Boston; Division of Human Genetics and Molecular Biology, Children's Hospital of Philadelphia; and Institut für Humangenetik der Justus-Liebig-Universität. Received for publication April 14, 2003; revised June 23, 2003.

DOI: 10.1097/01.PRS.0000122202.26792.BF

Synostotic frontal plagiocephaly is generally not considered to be inheritable. However, mutations have been found in some patients, the most common being *FGFR3* Pro250Arg.⁴⁻⁶ An *FGFR2* mutation was discovered in a family with variable sutural synostosis, including asymmetric coronal fusion presenting as frontal plagiocephaly.⁷ Asymmetric coronal synostosis, manifesting as synostotic frontal plagiocephaly, also occurs in approximately one-fourth of patients with Saethre-Chotzen syndrome, which is caused by various mutations in *TWIST*.⁸ In addition, synostotic frontal plagiocephaly is exhibited by one-half of patients with the rare craniofrontonasal syndrome,^{9,10} which is inherited as an X-linked trait.¹¹

This study analyzed a consecutive series of patients with synostotic frontal plagiocephaly who were admitted for primary surgical correction or seen for postoperative follow-up evaluation. The parents also were examined for dysmorphic features suggestive of coronal synostosis. Blood samples were drawn for mutational analysis in *FGFR1*, *FGFR2*, *FGFR3*, and *TWIST*. In those patients who were found to have a mutation, phenotypic findings, anthropometric data, and family history were reviewed, looking for clues that could have predicted the molecular change.

PATIENTS AND METHODS

Mutational Analysis

Blood samples were drawn on all infants undergoing operative correction for synostotic plagiocephaly during the period 1997 to 2000. In addition, mutational analysis was performed on children evaluated during this period following repair of this condition. Blood was taken from the parents of the child if there was any evidence of a cranial abnormality, such as unilateral or bilateral frontal retrusion, macrocephaly, hypertelorism, or anomalies of the hands or feet.

Ethylenediaminetetraacetic acid blood samples were analyzed by extracting DNA according to standard procedures. Analysis for the *FGFR1* Pro252Arg and the *FGFR3* Pro250Arg mutations was performed by polymerase chain reaction amplification, followed by restriction enzymatic digestion and

agarose gel electrophoresis.^{12,13} Exons 7 and 9 of the *FGFR2* gene were amplified using primers and conditions described by Steinberger et al.¹⁴ and by Meyers et al.,¹⁵ followed by single-strand conformation polymorphism analysis.¹⁶ Sequence analysis was performed either manually using the 33P-Thermo Sequenase radiolabeled terminator for cycle sequencing kit (Amersham Pharmacia Biotech, Piscataway, N.J.) or on an ABI 377 automated DNA sequencer. Sequence analysis of the *TWIST* gene coding region was performed, as described previously.¹⁷

Clinical and Anthropometric Analysis

The patients' records were reviewed, documenting head circumference, midfacial hypoplasia, blepharoptosis, cant of the palpebral fissures, and possible auricular and hand anomalies. Any dysmorphic features in the parents were also noted. Intraoperative anthropometric measures included sagittal distance from orbitale superius to apex corneae, inter medial canthal dimension, and nasal angulation. Instruments used for measuring included a metric ruler for the distance from orbitale superius to apex corneae, a sliding Vernier caliper for inter medial canthal dimension, and a nasal protractor for angulation of the root, as previously described.^{18,19} All measurements were performed three times by a single examiner (Mulliken) and the average or identical value was recorded. Accuracy was to the nearest 1 mm for distance from orbitale superius to apex corneae and the nearest 0.5 mm for the inter medial canthal distance. Anthropometric measures and the other physical findings were compared between infants discovered to have a mutation and those in whom a mutation was not found.

RESULTS

Mutational Analysis

A total of 47 patients with synostotic frontal plagiocephaly were evaluated during the 4-year study: there were 32 girls and 15 boys, for a 2:1 female preponderance. Mutations were found in eight patients, and a ninth patient was clinically diagnosed as syndromic, although the

TABLE I
Clinical and Anthropometric Findings in Patients with Synostotic Frontal Plagiocephaly and Molecular Diagnosis

Patient	Age	Family	Distance from Orbitale Superius to Apex Corneae		Inter Medial Canthal Dimension (mm)	Nasal Angle (degrees)	Mutation (gene and amino acid change)
			Ipsilateral/Contralateral				
1	9 mo	Mother: UCS	-1	+8	28	8	<i>FGFR3</i> Pro250Arg
2	2 yr	Negative	+4	+9	34.5	8	<i>FGFR3</i> Pro250Arg
3	33 yr	Daughter: BCS	-1	+6	40.5	11	<i>FGFR3</i> Pro250Arg
4	9 mo	Mother: BCS (inter medial canthal dimension 32 mm) Sister: pansynostosis (inter medial canthal dimension 35 mm at 20 mo)	-6	+4	35	8	<i>FGFR2</i> Ala344Ala
5	10 mo	Negative	-3	0	27	8	<i>FGFR2</i> Cys342Tyr
6	10 mo	Father: SCS Sister: SCS	-6	0	25	7	<i>TWIST</i> 417insLysIleIleProThrLeuPro (in-frame duplication)
7	9 mo	Father: SCS	-5	+2	34	10	<i>TWIST</i> Gln122STOP (nonsense)
8	10 mo	Mother: normal phenotype, same genetic alteration	-3	0	26	10	<i>TWIST</i> delAla87-Gly92 (in-frame deletion)
9	1 yr	Mother: CFNS	-2	+5	36	10	Causative gene on chromosome X

UCS, unilateral coronal synostosis; BCS, bilateral coronal synostosis; SCS, Saethre-Chatzen syndrome; CFNS, craniofrontonasal syndrome.



FIG. 1. Synostotic frontal plagiocephaly caused by *FGFR3* Pro250Arg mutation. (left) Patient 1 and (right) patient 2. Both have first-degree orbital hypertelorism.

mutated gene is unknown. These findings are summarized in Table I. The most common mutation was *FGFR3* Pro250Arg ($n = 3$) (Fig. 1). Two patients had different mutations in *FGFR2* (Fig. 2). Three of these five patients had a first-degree relative with either unilateral ($n = 1$) or bilateral frontal retrusion ($n = 2$). The parents of the other two patients with *FGFR*

mutations were normal by physical examination and molecular screening.

Three patients had a mutation in *TWIST* (Fig. 3). The diagnosis of Saethre-Chatzen syndrome had been predicted for two of these subjects because each had an affected parent. The parents of the third child with a *TWIST* mutation were considered to be phenotypically

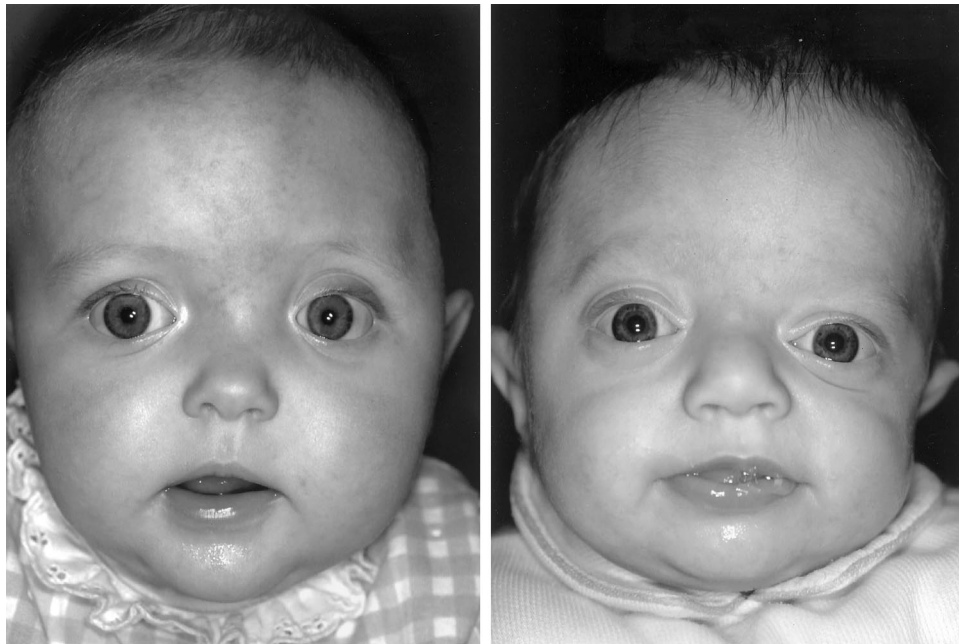

FIG. 2. Two infants with synostotic frontal plagiocephaly. (*Left*) Patient 4 (*FGFR2* Ala344Ala) with second-degree hypertelorism; (*right*) patient 5 (*FGFR2* Cys342Tyr) with normal inter medial canthal dimension.

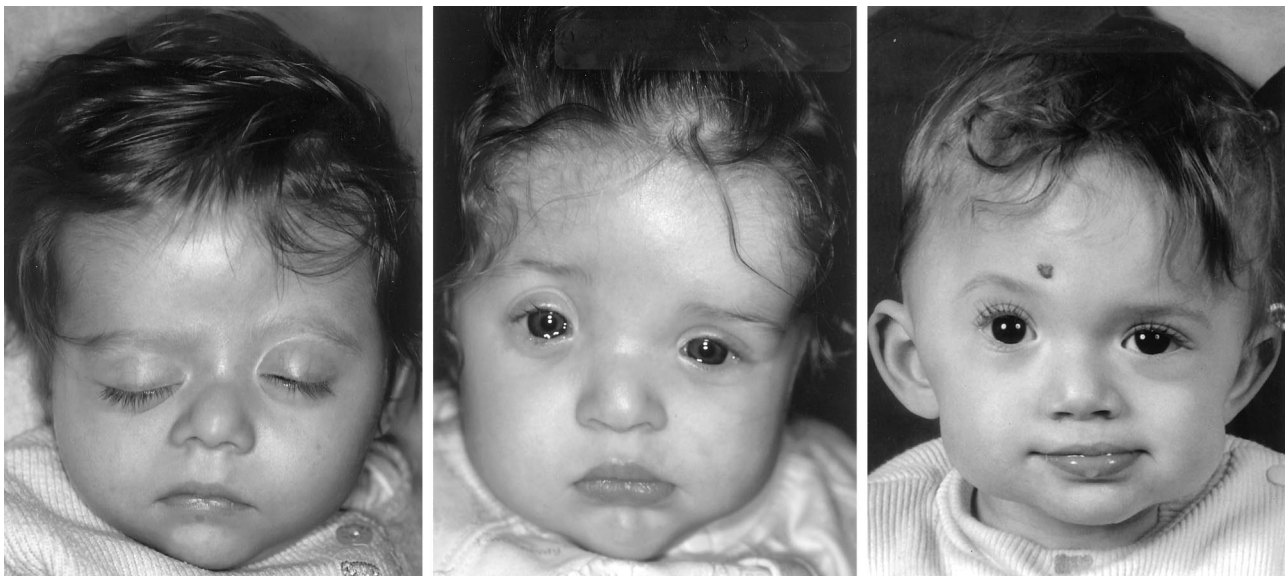

FIG. 3. Three infants with synostotic frontal plagiocephaly and *TWIST* mutations. (*Left*) Patient 6; note blepharoptosis. (*Center*) Patient 7; note low, upturned frontal hairline and second-degree hypertelorism. (*Right*) Patient 8; note contralateral rotation of midface and chin and incidental infantile hemangioma.

normal; however, molecular testing revealed that one had the same genetic alteration. One child had craniofrontonasal syndrome, as did her mother (Fig. 4).

Four patients with synostotic frontal plagiocephaly had a relative with typical features of either unilateral or bilateral coronal synostosis—yet DNA testing was negative for *FGFR1*, *FGFR2*, *FGFR3*, and *TWIST* (Fig. 5). The findings in this subset of putative patients are summarized in Table II.

Anthropometry

Intraoperative anthropometry was available in eight patients with a mutation, another patient with a putative locus, and in 23 of 38 patients without a mutation, including two of four patients who were suspected of having a mutation.

Orbitale Superius-Apex Corneae

The findings in the sagittal dimension are summarized in Table III. The difference in the distance from orbitale superius to apex corneae between the fused and nonfused sides was the same for both groups (approximately 6 mm), defined as with or without a detected mutation. However, the distance from orbitale superius to apex corneae for both the non-

fused and fused sides was significantly different between the two groups. This means there was a significant difference in the frontal projection between the patients with a mutation and those in whom a mutation was not found. On the normal side in the patients without a mutation, the mean distance from orbitale superius to apex corneae was 5.4 mm, whereas on the nonfused side in the mutated group, the mean was 2.6 mm. On the fused side in the patients without a mutation, the mean distance from orbitale superius to apex corneae was -0.50 mm, as compared with -3.6 mm in the patients with a mutation. In summary, there was no difference in the relative sagittal position of the supraorbital rims between the two groups. However, both sides of the supraorbital region were more retruded in those patients with a detectable mutation (and in the patients suspected of having a mutation) (Fig. 6).

Endocanthion-Endocanthion

Seven of eight patients found to have a mutation and the one infant with craniofrontonasal syndrome had orbital hypertelorism, defined as inter medial canthal dimension more than 2 SD for age- and sex-matched controls (Table I). Hypertelorism was also noted in all four patients suspected of having a mutation, although their molecular test results were negative (Table II). In contrast, the inter medial canthal distance was normal in the group without a mutation.

Nasal Angulation and Other Physical Findings

There was no significant difference in preoperative angulation of the nasal root for patients found to have a mutation versus those whose test results were negative (Table III), nor was there a consistent pattern in the position of the affected-side lateral canthus (relative to the medial canthus) that differentiated those infants with or without mutation. Macrocephaly also did not predict the finding of a mutation. None of the patients evidenced midfacial retrusion at the time of the study. Clinodactyly of the fifth finger was noted in one family suspected of having a mutation (patient 4); however, this is a common autosomal dominant trait.

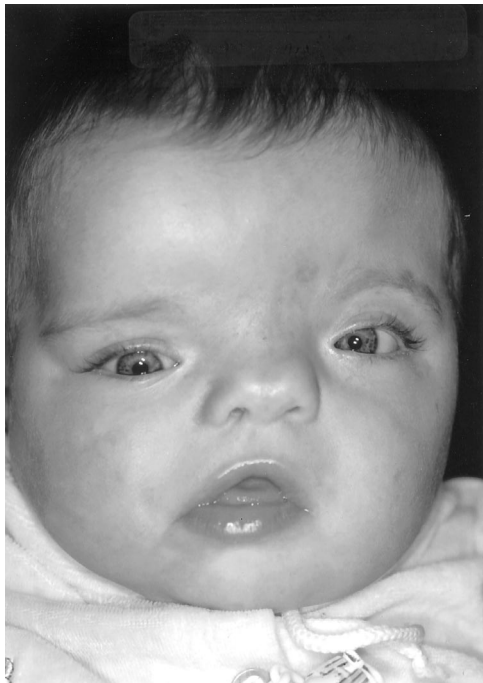


FIG. 4. Patient 9 with craniofrontonasal syndrome. Note left synostotic frontal plagiocephaly, short, bifid nose, second-degree hypertelorism, eurycephaly, and strabismus.

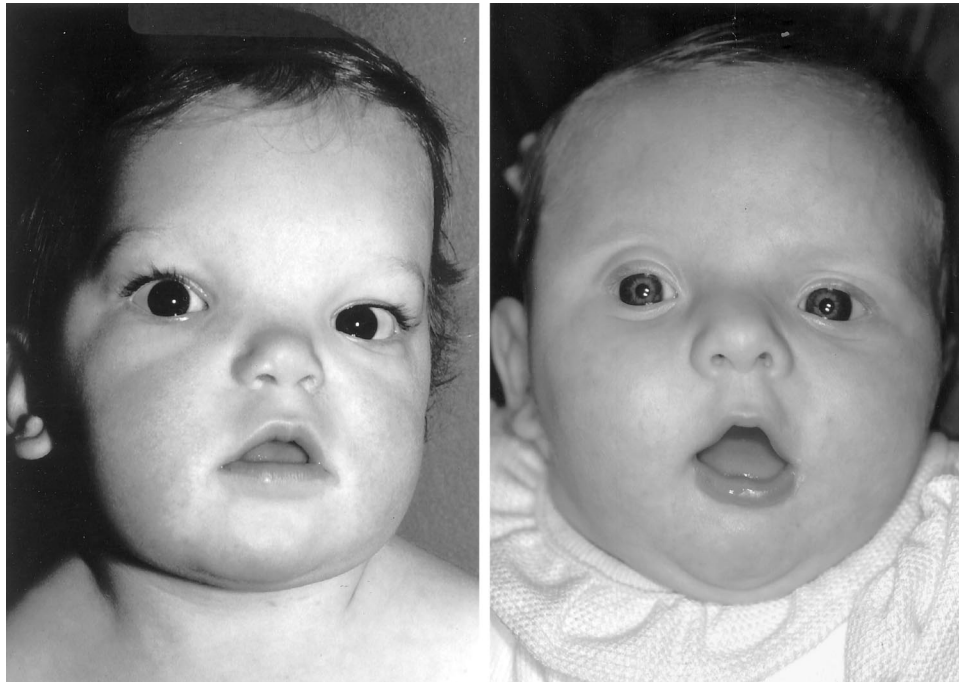

FIG. 5. Two infants with synostotic frontal plagiocephaly suspected of having a mutation because of anthropometric findings and positive family history, but no mutation detected. (Left) Patient 10; note high forehead, first-degree orbital hypertelorism. (Right) Patient 11 has borderline hypertelorism.

TABLE II

Clinical and Anthropometric Findings in Patients with Synostotic Frontal Plagiocephaly and Suspected Mutation

Patient	Age	Family	Distance from Orbitale Superius to Apex Corneae (mm)		Inter Medial Canthal Dimension (mm)	Nasal Angle (degrees)
			Ipsilateral/Contralateral			
10	5 mo	Mother: UCS, hypertelorism fifth toe clinodactyly Maternal grandmother: hypertelorism	N/A		30	N/A
11	7 mo	Maternal grandmother: BCS	-1	+5	28	9
12	22 mo	Mother: frontal retrusion	-4	+2	30	8
13	10 yr	Father: UCS	N/A		35	N/A

N/A, not available; BCS, bilateral coronal synostosis; UCS, unilateral coronal synostosis.

Revisions

Although the numbers are small, of possible importance was the finding that two of the five patients with an *FGFR* molecular diagnosis required revision of the forehead. Patient 2 had a second fronto-orbital advancement (the initial procedure was performed at another hospital) and patient 5 had a foreheadplasty in our unit. Furthermore, of the four patients suspected of having a mutation, one had a second fronto-orbital advancement and another will need a foreheadplasty. In contrast, to date, only six of 34 patients in whom a mutation was not identified either have had or will need frontal revision.

DISCUSSION

Genes Causing Bilateral Coronal Craniosynostoses

Many different mutations in genes coding for *FGFR1*, *FGFR2*, or *FGFR3* cause bilateral synostosis of the coronal ring, often in combination with fusion of other cranial sutures. When mutations in *FGFR2* first were detected in Crouzon syndrome,²⁰ it was thought that the genetic change (genotype) would predict the phenotype. This assumption turned out to be correct in Apert syndrome, which is caused by one of two adjacent mutations in the linker region between the immunoglobulin-like loops II and III of *FGFR2*.²¹ Another example of mo-

TABLE III
Anthropometric Measures: Comparison between Patients with and without a Detected Mutation

Measure	No Mutation			Mutation Found			<i>t</i>	<i>p</i>
	No. of Patients	Mean	SD	No. of Patients	Mean	SD		
Nasal angle (degrees)	23	8.52	2.13	9	8.50	1.07	0.27	NS
Distance from orbitale superius to apex corneae (mm), nonfused side	23	5.43	1.24	9	2.63	2.88	2.68*	0.03
Distance from orbitale superius to apex corneae (mm), fused side	23	-0.50	2.09	9	-3.63	2.00	3.68	<0.01
Distance from orbitale superius to apex corneae (mm), difference nonfused versus fused side	23	5.93	1.71	9	6.25	2.49	0.40	NS

* Variances were not equal across groups. The *t* test procedure does not assume equal variances was used for this measure. In all other measures, the variances were not significantly different and the standard *t* test assuming equal variances was applied.

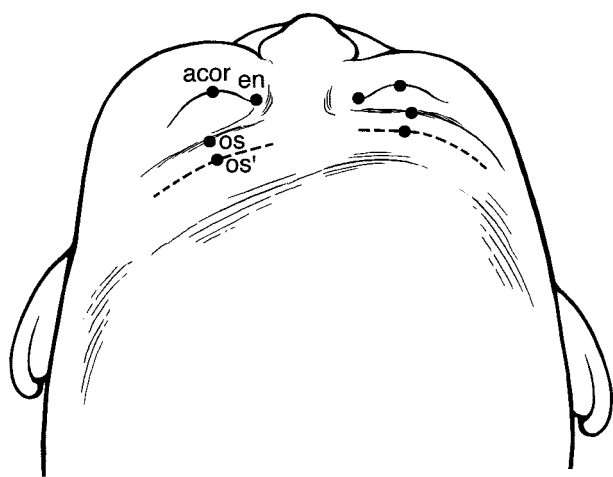


FIG. 6. Patients with a mutation and those suspected of having a mutation have bilateral (asymmetric) supraorbital retrusion (dotted line) and orbital hypertelorism (increased *en-en*). However, the distance from orbitale superius (*os*) to apex corneae (*acor*) was the same between fused and nonfused sides in patients, whether or not a mutation was detected.

lecular-clinical correlation is *FGFR3* (Ala391Glu), which is consistently found in patients with crouzonoid craniosynostosis and acanthosis nigricans.²²⁻²⁴ However, there is no clear genotype-phenotype correlation in most patients with bilateral coronal synostosis. Different mutations in one of the three *FGFR* genes can cause identical phenotypes, and mutations in the same genes can beget highly variable features (and different eponymous labels).²⁵ Even identical mutations in the same family can produce a wide spectrum of craniofacial manifestations that range from subtle dysmorphism, such as minor hypertelorism and minimally broad toes, to major changes caused by pansynostosis.²⁶

Mutations are known for the major “syn-

dromic” craniosynostoses. In a study of 50 patients with bilateral coronal synostosis, a molecular alteration in genes encoding fibroblast growth factor receptors 1, 2, and 3 was found in all those patients who had a clinical diagnosis of either Apert, Crouzon, or Pfeiffer syndrome.²⁴ A mutation was discovered in 75 percent of patients with unclassified brachycephaly, the most common being *FGFR3* Pro250Arg (Muenke syndrome).²⁴ In patients with a clinical diagnosis of Saethre-Chotzen syndrome, sequence analysis and Southern blot analysis or fluorescent in situ hybridization detected mutations in *TWIST* in 80 percent, including point mutations and deletions.^{17,27}

Genes Causing Single Sutural Synostosis

Imprecise usage of the designation “nonsyndromic” can cause confusion because it implies that a disorder is not genetic or not familial.¹ For example, this term is often misapplied to patients with bilateral coronal synostosis who do not have an easily recognizable eponymous phenotype.²⁸ Nonsyndromic is sometimes used in reference to single sutural synostosis involving either sagittal, coronal, metopic, or lambdoid junctures.²⁹ Indeed, a genetic abnormality is rarely found in a patient who has an isolated sutural fusion. However, such a patient could have an underlying genetic cause for the synostosis. Our current screening techniques have limitations and, furthermore, it is likely that there are undiscovered gene loci responsible for craniosynostosis.

Sagittal synostosis is the most common type of single sutural fusion. To date, no known mutations causing scaphocephaly have been identified, although this abnormality can be familial. In a large series of scaphocephalic patients, Lajeunie and colleagues determined that only 6 percent were familial, and segrega-

tion analysis indicated autosomal dominant transmission.³⁰ In Crouzon syndrome, sagittal and coronal synostosis can occur together in 19 percent of patients and combined sagittal-coronal-lambdoidal synostosis in 75 percent of patients.³¹ Metopic synostosis can occur with many other anomalies, some of which are known to be genetic.³² Lajeunie et al. found that only 5.6 percent of patients with isolated trigonocephaly were familial, 23 percent were syndromal, and 17 percent had trigonocephaly in association with other anomalies, usually involving the limbs, heart, genitourinary system, and brain.³³ Chromosomal analysis is indicated in evaluating a trigonocephalic infant because there is an association with a number of deletions and with aneuploidy.³² Unfortunately, karyotyping was available in only a small number of patients in the large series of Lajeunie et al.³³

Genes Causing Unilateral Coronal Synostosis

Unilateral fusion of the coronal ring, involving the frontoparietal and frontosphenoidal sutures, is usually considered to be nongenetic and nonsyndromic. However, a small proportion of these patients will be found to have an identifiable mutation in *FGFR 2*, *FGFR 3*, or *TWIST*, either de novo or inherited. The parents may be unaware of an inheritable condition until the birth of a child with synostotic frontal plagiocephaly. The first step is to examine the child and parents for evidence of bilateral frontal retrusion (distance from orbitale superius to apex corneae), orbital hypertelorism (inter medial canthal dimension), macrocephaly (cranial circumference), and hand and foot anomalies. Bilateral frontal recession and orbital hypertelorism could have a common pathogenesis. Although the frontoparietal suture is open on the contralateral side, there could be an abnormality in the basilar coronal suture.³ Thus, bilaterally diminished growth at the frontosphenoid and/or sphenoid could restrict supraorbital expansion and also cause transverse (compensatory) overgrowth of the ethmoidal complex.

There are other physical findings that are specific to patients who have one of the mutations known to cause syndromic unilateral coronal synostosis. In addition, a detailed family history may identify relatives with an abnormal cranial shape or those with a record of having had an operation for craniosynostosis.

FGFR2

Two patients with synostotic frontal plagiocephaly were identified as having an *FGFR2* mutation. Patient 4 had a G1032A transition (Ala344Ala), a common mutation for Crouzon syndrome. This does not result in an amino acid substitution but rather an abnormal splicing of the *FGFR2* transcript and a deletion of 12 amino acids in the immunoglobulin IIIc domain.³⁴ The same mutation was detected in the mother who had bilateral frontal retrusion and in the sister who had pansynostosis, which required total calvarial modeling. All three had second-degree orbital hypertelorism and minor hand anomalies (which are probably not associated with the mutation). A Turkish pedigree has been described with the same *FGFR2* Ala344Ala mutation. As in our family, there was a wide spectrum from minor to severe manifestations of craniosynostosis, but none of the affected members had synostotic frontal plagiocephaly.²⁶ Another child (patient 5) in our series had nonfamilial synostotic frontal plagiocephaly had the amino acid alteration *FGFR2* Cys342Tyr, another common mutation causing Crouzon syndrome. He had borderline orbital hypertelorism (1 SD above normal) but no hand abnormalities. There is also a documented family with another mutation in *FGFR2* (Lys292Glu) that caused variable phenotypes ranging from minor brachycephaly to synostotic frontal plagiocephaly.⁷

FGFR3

It has been suggested that *FGFR3* Pro250Arg is among the most common mutations in the human genome.³⁵ Approximately 10 percent of patients with the *FGFR3* Pro250Arg mutation have unilateral, rather than bilateral, coronal sutural fusion, and both phenotypes can occur in the same family.^{4,36} Clues to this mutation include a broad, high forehead with macrocephaly, down-slanting palpebral fissures, minor brachydactyly, and anomalous toes. Carriers of this mutation can have a subtle phenotype or they can be clinically normal.

On the basis of previous reports, the likelihood of finding the *FGFR3* mutation in patients with synostotic frontal plagiocephaly is low, for example, four of 37 (11 percent),^{5,37} two of 27 (7 percent),⁶ and three of 46 (6 percent).³⁸ Indeed, we found only three of 47 patients with *FGFR3* Pro250Arg; two were female and none had macrocephaly or digital

anomalies. This mutation was found in immediate relatives in two patients: one patient's mother had unilateral coronal synostosis and the other patient was the parent of a child with bilateral coronal synostosis. Test results of the parents of the third affected child were negative for the mutation.

Children who carry *FGFR3* Pro250Arg may be more likely to have an unsatisfactory outcome following operative correction. In a report from the Children's Hospital of Philadelphia, six patients with the *FGFR3* mutation had more severe cranio-orbital asymmetry, as measured by an orbital index.³⁷ The authors proposed that these patients were more likely to need surgical revision than those without the *FGFR3* mutation. One of our three *FGFR3* patients required a second fronto-orbital advancement (the initial procedure was performed elsewhere) to correct frontal asymmetry and recession, and a second child needed a foreheadplasty. Two of four patients in the group suspected of having a mutation needed a frontal revision.

TWIST

There is evidence that *TWIST* and *FGFR* are part of the same biochemical pathway involved in differentiation of cranial sutures.^{8,39} Saethre-Chotzen syndrome can be expressed as synostotic frontal plagiocephaly, as documented in 23 percent of patients in the series reported by Paznekas et al.⁸ Three patients in our study had a *TWIST* mutation. In two infants (patients 6 and 7), the molecular diagnosis was anticipated because the father had Saethre-Chotzen syndrome: one had bilateral frontal retrusion and the other had fronto-orbital asymmetry and deviation of the nasal root. Other well-known features of this condition include low frontal hairline with upturned follicles, blepharoptosis, small ears with prominent helical crura, and minor brachysyndactyly. Sometimes, these characteristics of Saethre-Chotzen syndrome are subtle in an infant. The discovery of a *TWIST* mutation in the third child (patient 8) in this series was unexpected. Rather, a *FGFR3* mutation had been suspected because of brachycephaly and bilateral (asymmetric) frontal retrusion, documented by intraoperative anthropometry. Of note, the specific mutation identified in this patient is an 18-pair deletion in a polyglycine tract. Variations in this glycine-rich region have been found in clinically normal individuals.⁴⁰ Although both parents ap-

peared to be normal, one parent was subsequently found to have the same genetic alteration as the affected child. There was also a history of craniosynostosis in a distant relative of this parent.

Craniofrontonasal Syndrome

Synostotic frontal plagiocephaly is reported to occur in 54 percent of patients who have the rare craniofrontonasal syndrome.^{9,10} In large families, craniofrontonasal syndrome was found to be transmitted as an X-linked dominant trait. The putative locus of the gene was initially mapped to the short arm,¹¹ but it was more recently linked to the pericentric region of the X chromosome.⁴¹ This condition is unusual in that, in contrast to other X-linked disorders, boys are typically less severely affected than girls. Linkage analysis can only be performed in very large families, but it is not diagnostic. One patient in our series (patient 9) had craniofrontonasal syndrome, as did her mother. The infant had typical features, including eurycephaly, third-degree orbital hypertelorism, a broad, short nose with bifid tip, scaphomaxillism, short neck, and narrowed, sloping shoulders. Low hairline, frizzy hair, and grooved nails did not become obvious until the child was older.

Familial Coronal Synostosis without an Identifiable Mutation

Neither *FGFR* nor *TWIST* mutations were found in four patients with synostotic frontal plagiocephaly. This is curious because all patients had craniosynostosis in an immediate relative and had phenotypic findings suggestive of an *FGFR* mutation. For example, all had orbital hypertelorism. Patient 12 had bilateral, asymmetrical supraorbital retrusion (distance from orbitale superius to apex corneae was only 2 mm on the "normal" side), whereas her mother had symmetrical frontal retrusion. The mother of patient 10 also had synostotic frontal plagiocephaly and hypertelorism; the latter was also documented in the maternal grandmother. Another infant in this putative group (patient 11) had normal sagittal projection of the contralateral supraorbital rim and his mother was considered normal, but his maternal grandmother had had a coronal "strip" craniectomy in infancy.

It is likely that each of these four children has a causative mutation. The mutations could be in the known genes that were missed be-

cause we did not sequence the entire coding region. An alternative and more likely explanation is that these families segregate bilateral and unilateral coronal craniosynostosis linked to an unknown locus. Another, and believed to be least likely, interpretation is somatic mosaicism for a mutation affecting one side of the frontoparietal-frontosphenoidal suture.

CONCLUSIONS

Given the current state of our knowledge, discovery of a molecular change in a child with synostotic frontal plagiocephaly is infrequent. Nevertheless, every child with this phenotype and the child's parents should be carefully examined and a detailed family history should be obtained. Molecular testing is available on a clinical basis. DNA analysis is particularly indicated if there is a positive family history of craniosynostosis, suspicious features in a parent, or additional findings in the child, such as a broad forehead, bilateral (asymmetrical) supraorbital retrusion, minor hypertelorism, or subtle anomalies of the hands. The finding of a dominant mutation in *FGFR2*, *FGFR3*, or *TWIST* in such a circumstance has obvious importance for counseling the parents and the patient.⁴²

Knowledge of a molecular diagnosis also alerts the surgeon. Preoperative anthropometric documentation of supraorbital rim-to-corneal apex (distance from orbitale superius to apex corneae) has technical implications. Those infants with synostotic frontal plagiocephaly without an identifiable mutation usually have a normal distance from orbitale superius to apex corneae on the contralateral side and, consequently, fronto-orbital advancement is only necessary on the affected side. However, those infants found to have a mutation (or suspected of having a mutation) exhibit bilateral supraorbital recession and, consequently, bilateral (asymmetrical) advancement of the bandeau is necessary.

John B. Mulliken, M.D.
Division of Plastic Surgery
Children's Hospital
300 Longwood Avenue
Boston, Mass. 02115
john.mulliken@childrens.harvard.edu

ACKNOWLEDGMENTS

Supported in part by grant STE 770/1 from the Deutsche Forschungsgemeinschaft (to D.S. and U.M.). The authors thank Richard A. LaBrie, M.D., for statistical analysis; Ethylin

Wang Jabs, M.D., for molecular finding in one family; D. McGain, B.S., for assistance with mutation analysis; and E. H. Zackai, M.D., for expert advice.

REFERENCES

- Mulliken, J. B. The craniofacial surgeon as amateur geneticist. *J. Craniofac. Surg.* 13: 3, 2002.
- Bruneteau, R. J., and Mulliken, J. B. Frontal plagiocephaly: Synostotic, compensational, or deformational. *Plast. Reconstr. Surg.* 89: 21, 1992.
- Rogers, G. F., Proctor, M. R., and Mulliken, J. B. Isolated synostosis of the frontosphenoidal suture: An uncommon cause of synostotic frontal plagiocephaly. *Plast. Reconstr. Surg.* 109: 1011, 2002.
- Muenke, M., Gripp, K. W., McDonald-McGinn, D. M., et al. A unique point mutation in fibroblast growth factor receptor 3 gene (*FGFR3*) defines a new craniosynostosis syndrome. *Am. J. Hum. Genet.* 60: 555, 1997.
- Gripp, K. W., McDonald-McGinn, D. M., Gaudenz, K., et al. Identification of a genetic cause for isolated unilateral coronal synostosis: A unique mutation in the fibroblast growth factor receptor 3. *J. Pediatr.* 132: 714, 1998.
- Lajeunie, E., El Ghouzzi, V., LeMerrer, M., et al. Sex related expressivity of the phenotype in coronal craniosynostosis caused by the recurrent P250R *FGFR3* mutation. *J. Med. Genet.* 36: 9, 1999.
- Steinberger, D., Collmann, H., Schmalenberger, B., and Müller, U. A novel mutation (a886g) in exon 5 of *FGFR2* in members of a family with Crouzon phenotype and plagiocephaly. *J. Med. Genet.* 34: 420, 1997.
- Paznekas, W. A., Cunningham, M. L., Howard, T. D., et al. Genetic heterogeneity of Saethre-Chotzen syndrome due to *Twist* and *FGFR2* mutations. *Am. J. Hum. Genet.* 62: 1370, 1998.
- Saavedra, D., Richieri-Costa, A., Guion-Almeida, M.-L., and Cohen, M. M., Jr. Craniofrontonasal syndrome: Study of 41 patients. *Am. J. Med. Genet.* 61: 147, 1996.
- Cohen, M. M., Jr. Craniofrontonasal syndrome. In M. M. Cohen, Jr., and R. E. MacLean (Eds.), *Craniosynostosis: Diagnosis, Evaluation, and Management*, 2nd Ed. New York: Oxford University Press, 2000. Pp. 380-384.
- Feldman, G. J., Ward, D. E., Lajeunie-Renier, E., et al. A novel phenotypic pattern in X-linked inheritance: Craniofrontonasal syndrome maps to Xp22. *Hum. Mol. Genet.* 6: 1937, 1997.
- Schell, U., Hehr, A., Feldman, G. J., et al. Mutations in the *FGFR1* and *FGFR2* cause familial and sporadic Pfeiffer syndrome. *Hum. Mol. Genet.* 4: 323, 1995.
- Bellus, G. A., Gaudenz, K., Zackai, E. H., et al. Identical mutations in three different fibroblast growth factor receptor genes in autosomal dominant craniosynostosis syndromes. *Nat. Genet.* 14: 174, 1996.
- Steinberger, D., Mulliken, J. B., and Müller, U. Predisposition for cysteine substitutions in the immunoglobulin-like chain of *FGFR2* in Crouzon syndrome. *Hum. Genet.* 96: 113, 1995.
- Meyers, G. A., Day, D., Goldberg, R., et al. *FGFR2* exon IIIa and IIIc mutations in Crouzon, Jackson-Weiss, and Pfeiffer syndromes: Evidence for missense changes, insertions, and a deletion due to alternative RNA splicing. *Am. J. Hum. Genet.* 58: 491, 1996.
- Orita, M., Iwahana, H., Kanazawa, H., et al. Detection

- of polymorphisms of human DNA by gel electrophoresis as single-strand conformation polymorphisms. *Proc. Natl. Acad. Sci. U.S.A.* 86: 2766, 1989.
17. Gripp, K. W., Zackai, E. H., and Stolle, C. A. Mutations in the human *TWIST* gene. *Hum. Mutat.* 15: 150, 2000.
 18. Mulliken, J. B., Godwin, S. L., Prachartam, N., and Altobelli, D. E. The concept of the sagittal orbital-globe relationship in craniofacial surgery. *Plast. Reconstr. Surg.* 97: 700, 1996.
 19. Hansen, M., Padwa, B. L., Scott, R. M., Stieg, P. E., and Mulliken, J. B. Synostotic frontal plagiocephaly: Anthropometric comparison of three techniques for surgical correction. *Plast. Reconstr. Surg.* 100: 1387, 1997.
 20. Reardon, W., Winter, R. M., Rutland, P., et al. Mutations in the fibroblast growth factor receptor 2 gene cause Crouzon syndrome. *Nat. Genet.* 8: 98, 1994.
 21. Wilkie, A. O. M., Slaney, S. F., Oldridge, M., et al. Apert syndrome results from localized mutations of *FGFR2* and is allelic with Crouzon syndrome. *Nat. Genet.* 9: 165, 1995.
 22. Meyers, G. A., Orlow, S. J., Munro, I. R., et al. Fibroblast growth factor receptor 3 (*FGFR3*) transmembrane mutation in Crouzon syndrome with acanthosis nigricans. *Nat. Genet.* 11: 462, 1995.
 23. Wilkes, D., Rutland, P., Pulleyn, L. J., et al. A recurrent mutation, Ala391Glu, in the transmembrane region of *FGFR3* causes Crouzon syndrome and acanthosis. *J. Med. Genet.* 33: 744, 1996.
 24. Mulliken, J. B., Steinberger, D., Kunze, S., and Müller, U. Molecular diagnosis of bilateral coronal synostosis. *Plast. Reconstr. Surg.* 104: 1603, 1999.
 25. Rutland, P., Pulleyn, L. J., Reardon, W., et al. Identical mutations in the *FGFR2* gene cause both Pfeiffer and Crouzon phenotypes. *Nat. Genet.* 8: 275, 1995.
 26. Steinberger, D., Reinhartz, T., Unsöld, R., and Müller, U. *FGFR2* mutation in clinically nonclassifiable autosomal dominant craniosynostosis with pronounced phenotypic variation. *Am. J. Med. Genet.* 66: 81, 1996.
 27. Johnson, D., Horsley, S. W., Moloney, D. M., et al. A comprehensive screen for *TWIST* mutations in patients with craniosynostosis identifies a new microdeletion syndrome of chromosome band 7p21.1. *Am. J. Hum. Genet.* 63: 1282, 1998.
 28. Renier, D., El Ghouzzi, V., Bonaventure, J., et al. Fibroblast growth factor receptor 3 mutation in nonsyndromic coronal synostosis: Clinical spectrum, prevalence, and surgical outcome. *J. Neurosurg.* 92: 631, 2000.
 29. Perlyn, C. A., Marsh, J. L., Pilgram, T. K., and Kane, A. Plasticity of the endocranial base in nonsyndromic craniosynostosis. *Plast. Reconstr. Surg.* 108: 294, 2001.
 30. Lajeunie, E., LeMerrer, M., Bonaïti-Pellie, C., et al. Genetic study of scaphocephaly. *Am. J. Med. Genet.* 62: 282, 1996.
 31. Kreiborg, S. Crouzon syndrome: A clinical and roentgenocephalometric study. *Scand. J. Plast. Reconstr. Surg. Suppl.* 18: 1, 1981.
 32. Gorlin, R. J., Cohen, M. M., Jr., and Hennekam, R. C. M. *Syndromes of the Head and Neck*, 4th Ed. New York: Oxford University Press, 2001.
 33. Lajeunie, E., LeMerrer, M., Marchac, D., and Renier, D. Syndromal and nonsyndromal primary trigonocephaly: Analysis of a series of 237 patients. *Am. J. Med. Genet.* 75: 211, 1998.
 34. Li, X., Park, W.-J., Pyeritz, R. E., and Jabs, E. W. Effect on splicing of a silent *FGFR2* mutation in Crouzon syndrome. *Nat. Genet.* 9: 232, 1995.
 35. Moloney, M. P., Wall, S. A., Ashworth, G. J., et al. Prevalence of Pro250Arg mutation in fibroblast growth factor receptor 3 in coronal craniosynostosis. *Lancet* 349: 1059, 1997.
 36. Reardon, W., Wilkes, D., Rutland, P., et al. Craniosynostosis associated with the *FGFR3* pro250arg mutation results in a range of clinical presentations including unisutural sporadic craniosynostosis. *J. Med. Genet.* 34: 632, 1997.
 37. Cassileth, L. B., Bartlett, S. P., Glat, P. M., et al. Clinical characteristics of patients with unilateral coronal synostosis and mutations of fibroblast growth factor receptor 3: A preliminary report. *Plast. Reconstr. Surg.* 108: 1849, 2001.
 38. Renier, D., El Ghouzzi, V., Bonaventure, J., LeMerrer, M., and Lajeunie, E. Fibroblast growth factor receptor 3 mutation in nonsyndromic coronal synostosis: Clinical spectrum, prevalence, and surgical outcome. *J. Neurosurg.* 92: 631, 2000.
 39. Rice, D. P. C., Åberg, T., Chan, Y.-S., et al. Integration of *FGFR* and *TWIST* in calvarial bone and suture development. *Development* 127: 1845, 2000.
 40. Elanko, N., Sibbring, J. S., Metcalf, K. A., et al. A survey of *TWIST* for mutations in craniosynostosis reveals a variable length polyglycine tract in asymptomatic individuals. *Hum. Mutat.* 18: 535, 2001.
 41. Wieland, I., Jakubiczka, S., Muschke, P., et al. Mapping of a further locus for X-linked craniofrontonasal syndrome. *Cytogenet. Genome Res.* 99: 285, 2002.
 42. Zackai, E. H., Gripp, K. W., and Stolle, C. A. Craniosynostosis: Molecular testing. A necessity for counseling (Letter). *Am. J. Med. Genet.* 92: 157, 2000.